



NATIONAL VETERINARY LABORATORY

P.O. Box 239, 1Tice Road
Franklin Lakes, NJ 07417
877-NVL-LABS (877-685-5227)
www.natvetlab.com

NEWSLETTER

The Human *Bartonella* Paradigm Has Changed[©]

Evelyn E. Zuckerman, Editor

Summer 2015

Vol. 14 Number 3

In This Issue:

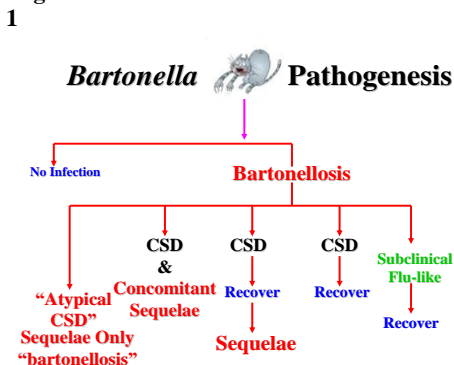
The Summer 2015 NVL Newsletter will again review the human *Bartonella* paradigm. The Oxford English Dictionary defines *paradigm* as "a typical example or pattern of something; a pattern or model. The human *Bartonella* paradigm has changed as the ability to isolate *Bartonella* has improved and more studies have been completed.¹⁻⁵ As of July 1, 2015 there are 4,619 *Bartonella* publications, listed in the National Library of Medicine, approximately 40% of which are human cases.

Human *Bartonella* Paradigm:

Presently, there are 34 *Bartonella* species of which at least 15 have been shown to cause disease in humans. The most common human pathogenic *Bartonella* species is *Bartonella henselae* derived from cats which can cause severe disease in various major organ systems including the heart, brain, eye, and lungs. The term cat scratch disease (CSD) is commonly used to include all the pathogenic consequences of *Bartonella* infections of humans. A more precise term is bartonellosis which indicates all the *Bartonella*-induced clinical syndromes in people including the classical CSD and the more severe inflammatory diseases of various organ systems.

The former human *Bartonella* paradigm stated that *Bartonella* caused CSD, a self-limiting condition, occurring mostly in children, characterized by fever, a papule at the scratch site and regional lymphadenopathy. Most cases resolved without antibiotic therapy although there is rare systemic involvement in major organs. In the new paradigm, bartonellosis consists of CSD and more clinically significant, rarely life-threatening pathology in major organ systems.

Figure 1



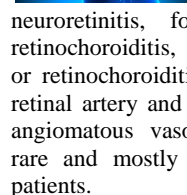
In Figure 1, we list the possible outcomes of exposure to *Bartonella* from cats. The scratch or bite of an infected cat most often results in no infection. However, when *Bartonella* is transferred from cats there are 5 possible outcomes under the definition of bartonellosis. Reading from right to left in figure 1: 1) infection can result in a mild or subclinical "flu-like" illness which may last a few days before full recovery and clearing of the infection; 2) infection can result in the classic CSD syndrome of fever, papule and lymphadenopathy followed by resolution and clearing of the infection; 3) infection can result in the classic CSD syndrome with clinical resolution but with persistence of the infection and subsequent development of "atypical CSD" or sequelae which are listed in the publication by Kalogeropoulos et. al. below; 4) infection can result in the classic CSD syndrome with concurrent development of sequelae (atypical CSD); and finally; 5) infection can result in no signs of the classic CSD syndrome but only the development of sequelae (atypical CSD). Unfortunately, many physicians are not familiar with the new *Bartonella* paradigm and the extent of *Bartonella*-induced clinical alterations.

Kalogeropoulous and colleagues have published an excellent summary of the human *Bartonella henselae* diseases which I reproduce verbatim below. We consider the inflammatory conditions, 1 through 9, as CSD sequelae or atypical CSD.

Kalogeropoulous C. et al *Bartonella* and intraocular inflammation: a series of cases and review of literature. Clinical Ophthalmology 2011;5 817-829, Dove Medical Pres, Ltd. Open Access.

1. Fever of unknown origin (FUO). Prolonged fever. 2 weeks without any symptoms or signs of an obvious clinical disease.

2. Ocular manifestations: Parinaud oculoglandular syndrome consists of follicular conjunctivitis and regional lymphadenopathy. Posterior segment manifestations include neuroretinitis, focal retinitis, choroiditis or retinochoroiditis, multifocal retinitis, choroiditis or retinochoroiditis, intermediate uveitis, branch retinal artery and vein occlusions, vasculitis and angiomatous vasoproliferative lesions that are rare and mostly seen in immunocompromised patients.



3. Other clinical manifestations hepatosplenic manifestations: granulomatous and suppurative disease of the liver and spleen with systemic symptoms as prolonged fever and with or without abdominal pain, hepatomegaly or splenomegaly.

4. Cardiovascular manifestations: Endocarditis is the most common cardiac complication. *Bartonella* species are responsible for about 3% of cases of endocarditis. Myocarditis is a rare complication.

5. Neurologic manifestations: They are rare and include encephalopathy, seizures, status epilepticus, meningitis, meningoencephalitis, peripheral facial nerve paralysis, coma, transverse myelitis and acute hemiplegia.

6. Hematologic manifestations: They are rare and include hemolytic anemia and thrombocytopenic purpura.

7. Renal manifestations: Glomerulonephritis is a rare complication.

8. Orthopedic manifestations: Osteomyelitis and arthritis are rare complications.

9. Pseudomalignancy: Simulating lymphoma, mimicking breast tumor, simulating a malignant process of the chest wall, simulating rhabdomyosarcoma, mimicking parotid malignancy.

In immunocompromised patients the response is mainly vasoproliferative:

Bacillary angiomatosis: Refers to skin proliferative vascular lesions that may resemble Kaposi's sarcoma. Red or brown papules, angiomatous nodules, pedunculated lesions, or deep subcutaneous masses.

Bacillary peliosis: Refers to proliferative vascular lesions in liver and spleen.

An underappreciated aspect of chronic *Bartonella* infections in people is the vague debilitating symptoms reported by many people. These chronic, vague, clinical symptoms are often dismissed by their physicians and thus, these people suffer until eventually bartonellosis is considered by an open-minded, knowledgeable physician as is illustrated in the publication by Hill and his colleagues below.

Generalized Bartonellosis Symptoms:

Hill DS. Atypical Adenopathy Associated with Cat Scratch Disease in a Chronically Ill Woman. J Diag Med Sonography 26:39-41, 2015.

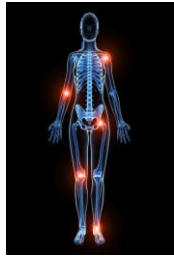This case illustrates the possible generalized debilitating effects of bartonellosis in some patients. A woman in her mid-40s had a long-term undiagnosed chronic illness that persisted for more than 2 years. Her multiple symptoms were general achiness, fatigue, painful joints, motor difficulties, cognitive difficulties and exhaustion.

Possible etiologies were investigated including multiple sclerosis, chronic EBV, Lyme disease, chronic fatigue syndrome, fibromyalgia, and chronic hepatitis. All were negative or inconclusive. She then developed a painful soft tissue mass on her distal left upper arm, superior to her elbow. The mass was surgically excised and gross pathology revealed an inflamed enlarged, lymph node. Immunologic evaluation revealed the presence of *Bartonella henselae*. The patient owned 3 cats but could not remember having been scratched or bitten by them or any other cats. After an 8 week regime of azithromycin, doxycycline and ciprofloxacin, all of her chronic, 2 year long, symptoms and the enlarged lymph node resolved fully. As we have recommended for the past 15 years for therapy of infected cats, these authors used long term antibiotic therapy that included azithromycin with a successful clinical outcome.³

We have commonly seen this syndrome in our studies of over 300 cat owners whose cats we have tested.^{4,5} Unfortunately we have interviewed many cat owners with a similar clinical course where it took years before chronic bartonellosis was diagnosed. In many cases these cats' owners were assisted in their medical course by their veterinarian suggesting the possibility of *Bartonella* infection from their cats.

Robert SC, Forbes SH, Soleimanian S, and Hadley JS. Complements do not lie. BMJ Case Reports doi.10.1136/bcr.08.2011.4705 2011.

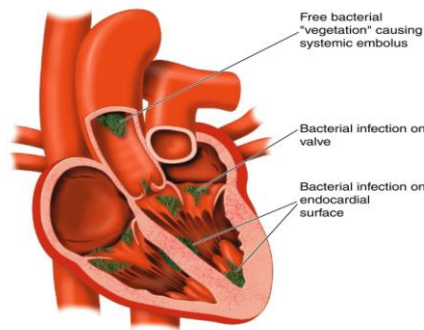
A 74-year-old man presented with 10 weeks of general malaise, lethargy, anorexia and 13% loss of body weight. He also had 2 episodes of confusion. He had a history of a bovine aortic valve replacement 6 years earlier and had 2 cats at home. A clinical workup revealed acute glomerulonephritis, pancytopenia, splenomegaly, thrombocytopenia, fever and low complement. Several blood cultures were negative and he was discharged on antibiotics without a diagnosis. One month later his condition deteriorated and he was readmitted to ICU requiring mechanical ventilation and renal replacement therapy. At this time, the screen for atypical organisms showed a high titer against *Bartonella henselae* IgG ($\geq 1:512$) and a low titer to *Coxiella* spp (1:80). All others were negative. He was treated with clarithromycin 500 mg BID



and gentamicin 80 mg SID. Within 3 days there was a dramatic improvement, he was removed from mechanical ventilation and renal replacement therapy. He was discharged, fully recovered, after 6 weeks of antibiotic therapy. Of note, the blood culture and PCR were both negative whereas the *Bartonella henselae* serology was strongly positive. The authors concluded that without the diagnosis of bartonellosis the outcome may have been significantly different and the patient may not have survived. This report shows that serology was the most accurate technique for detection of chronic *Bartonella* infection in this case.

Heart:

The heart is a very common site for *Bartonella* inflammation in people. The following publication, by an internationally prominent infectious disease group, shows that selecting the proper laboratory tests is critical for an accurate diagnosis of bartonellosis.



Edouard, S, Nabet C, Lepidi H, Fournier PE, Raoult, D. Bartonella, a common cause of endocarditis: a report of 106 cases and review. J Clin Microbiol. 53: 824-829, 2015.

This group reported 59 of their cases of *Bartonella*-induced endocarditis and a review of the literature between 2005-2013 for a total of 106 cases. The diagnosis was based on the Duke criteria and microbiological findings. They used *Bartonella* indirect immunofluorescence assays (IFA), Western blot serology, and real-time PCR on whole blood, serum and valve tissue. The sensitivities of these assays for detection of *Bartonella* are given in Table 1.

Table 1 Bartonella Comparison Tests

Assay	Sensitivity
IFA IgG	58%
Western blot IgG	100%
PCR: whole blood	33%
serum	36%
valve tissue	91%

The authors concluded that the major Duke criteria for the diagnosis of *Bartonella* endocarditis should be a positive PCR from the cardiac valve or blood, or an IgG titer of $\geq 1:800$ by IFA or a positive Western blot serology. As can be seen from Table 1, the most accurate assay for detection of the *Bartonella* etiology of culture negative human endocarditis is Western blot serology. We have used the Western blot for detection of *Bartonella* infections as we find it to be the most accurate, reproducible and sensitive serological assay.

One the lighter side- One Health;

Rasis M, Rudoler N, Schwartz D, Giladi M. Bartonella dromedarii sp. Nov. Isolated from Domesticated Camels (Camelus dromedaries) in Israel. Vector-Borne and Zoonotic Dis. 14:775-782, 2014.

Bartonella are found in a wide range of wild and domestic animals and the majority exhibit restricted host specificity. Many are known to be of zoonotic importance. Hematophagous arthropod vectors, fleas, biting flies, lice, mites, and ticks, have been found to be naturally infected and often implicated in transmission to people. Dromedary camels have a close association with humans and are used for transportation, milk, meat and wool and thus may be a source for zoonotic infections. Camels have recently been implicated as a possible reservoir for the MERS coronavirus.



Dr. Hardy on a camel- pyramids of Giza, Egypt.

This group isolated the first camel *Bartonella* spp and found it to be closely related to *B. chomelii*, *B. capreoli*, and *B. birtlesii*. They named the new isolate *Bartonella dromedarii* sp. nov. Studies to determine if this new species is zoonotic and pathogenic for humans are underway.

Summary: Feline Bartonella are not your mother's benign CSD pathogen any longer, they can cause widespread chronic inflammatory bartonellosis in many vital organs.

References:

1. Maggi, RG., Duncan, AB., Breitschwerdt, EB. Novel chemically defined liquid medium for the growth, as single or composed culture, and the primary isolation of *Bartonella* species from blood and body fluids. J Clin Microbiol. 43:2651-5, 2005.
2. Breitschwerdt EB. Feline bartonellosis and cat scratch disease. Vet. Immun & Immunopath. 123:167-171, 2008.
3. Hardy, WD, Jr., Zuckerman, EE, Corbishley, J, Gold, JWM, Baron, P, Polsky, B, Gilhuley, K, Kiehn, TE, and Armstrong, DA. Efficacy of high dose, long duration Doxycycline or Azithromycin treatment for *Bartonella* infections in pet cats. International Conference of the American Society for Rickettsiology, Big Sky, Montana, August 17-22, 2001.
4. WD Hardy, Jr., and EE Zuckerman, Human bartonellosis: diseases caused by feline *Bartonella*- 84 cases. The 5th International Conference on *Bartonella* as Emerging Pathogens. Pacific Grove, California, September 2-7 2006.
5. William Hardy, Jr, and Evelyn Zuckerman, *Bartonella*: The pet cat-human connection. EcoHealth 7: S67, 2011.

Bartonella references can be obtained at:

www.nlm.nih.gov/or natvetlab.com

©National Veterinary Laboratory, Inc., 2015