



NATIONAL VETERINARY LABORATORY

P.O. Box 239, 1Tice Road
Franklin Lakes, NJ 07417
877-NVL-LABS (877-685-5227)

www.natvetlab.com

NEWSLETTER

Bartonella Diseases in Veterinarians, Their Families and Employees, and Their Cat Owner Clients[©]

Spring 2003

Vol. 2, Number 2

Evelyn E. Zuckerman, Editor

In This Issue:

The spring 2003 issue of the NVL Newsletter will document the dangers of feline *Bartonella* for veterinarians, their families and employees and cat owners. These cases support our recommendation that all healthy cats, especially kittens, should be tested for *Bartonella*.

Bartonella and Veterinarians

Background:

Veterinarians and their employees are at higher risk for infection with *Bartonella* from cats than the general public.¹ In fact, one of the 6 feline *Bartonella* species, *Bartonella clarridgeiae*, was initially isolated from a veterinarian who was bitten by a 6-week-old kitten. In general, 20% of healthy pet cats in the USA are infected with *Bartonella*. Thus veterinarians and their staffs handle numerous infected cats in their daily occupation. A recent study found that 35 of the 233 (15%) veterinarians and veterinary technicians had antibody to *B. henselae* whereas only 7 of the 155 (4.5%) control group of medical students were antibody positive¹

Cat and dog fleas, and probably ticks, can carry and transmit *Bartonella* from cat to cat and probably from cat to dogs and cat to humans. However, it seems possible, although not proven, that direct cat-to-cat transmission via scratches and bites, can transmit *Bartonella* from cat to cat as often as direct cat to human transmission occurs.

The oral cavity is the site for transfer of *Bartonella*, during grooming, to the nails and fur of infected cats. Cats can transmit the bacteria from their infected nails by scratches or from the fur by contact. The oral cavity is the obvious exit port for bite transmission to people. The presence of fleas is not needed for transmission of *Bartonella* from cats to humans. However, *Bartonella* probably occasionally are directly transmitted to people via cat and dogs fleas and ticks.

Bartonella infection and disease occur equally in people younger and older than 21 years of age.² In addition, *Bartonella* infection occurs more in immunocompetent than immunosuppressed people. Kittens are more likely to transmit *Bartonella*, especially to children, because they

tend to playfully scratch and bite children more often than do adult cats. Boys are more often infected because they play more roughly with the kittens than do girls. Since kittens chew objects and have changing dentition, *Bartonella* are able to enter their oral cavity, through abrasions to their oral mucosa and through tooth sockets, to be transferred during grooming to the fur and nails. In this regard, cats with oral inflammatory disease: gingivitis, stomatitis, and oral ulcers, with inflamed and bleeding oral tissues are probably more likely to transmit *Bartonella* to people

Since *Bartonella* diseases are not reportable diseases an accurate incidence in humans has not been established. Previous estimates for cat scratch disease (CSD), only one of the 22 human *Bartonella* diseases, is 22,000 cases per year, of which 2,000 require hospitalization. CSD is the "tip of the iceberg" of a very large number (22) of little recognized *Bartonella* diseases of humans. The occurrence of all the *Bartonella* diseases (see Table below) in veterinarians, their family members or their employees has not been ascertained. It must be emphasized that many physicians are not familiar with the full range of *Bartonella* clinical diseases.^{2, 3, 4, 5, 6}

FELINE BARTONELLA-INDUCED DISEASES IN HUMANS

Previously Described Human Diseases:

Cat Scratch Disease
Bacillary angiomatosis & peliosis
Febrile bacteremia
Lymphadenopathy
Endocarditis & vegetative valvular disease
Uveitis
Neurological disorders
Anemia
Neuroretinitis- chorioretinitis
Osteomyelitis

Newly Described Human Diseases:

Inflammatory bowel disease
Mononucleosis-like syndrome
Co-infection with Lyme disease
Pulmonary infiltrates
Meningoencephalitis
Arthralgia & Myositis
Juvenile arthritis
Cutaneous rash- Henoch-Schenlein purpura
Cutaneous granuloma annulare
Disciform keratitis

Case Studies:

Veterinarian:

Case 1: Myositis

A 32-year-old male veterinarian, in small animal practice in New York City, developed muscle and joint pain that persisted for 4 years. Numerous diagnostic tests, including muscle biopsies, failed to find an infectious cause for his symptoms. Treatment by a rheumatologist consisted of corticosteroids which were effective in temporarily alleviating the discomfort. After learning about a case of myositis in a Florida cat, caused by *Bartonella*, that was cured by azithromycin therapy, the veterinarian sought a *Bartonella* test. His *Bartonella* serologic test was positive with an IgG titer of 1:128. Treatment with azithromycin resulted in resolution of the muscle and joint pain within 7 days. The symptoms of myositis have not recurred during the 3 months post azithromycin therapy period.

Family Member of a Veterinarian:

Case 2: Henoch-Schenlein Purpura

After attending a *Bartonella* lecture, a New York City veterinarian called this laboratory to discuss the possibility that his 17-month-old son, who had a persistent red rash on his right forearm, may have Henoch-Schenlein purpura, a cutaneous rash that can be caused by several bacteria, one of which is *Bartonella*. The cat, that had continually licked the boy's right hand, tested positive for *Bartonella*. The veterinarian arranged for his pediatrician to test his son for *Bartonella*. The boy's test was indeterminate for *B. henselae* antibody. The rash resolved without antibiotic therapy.

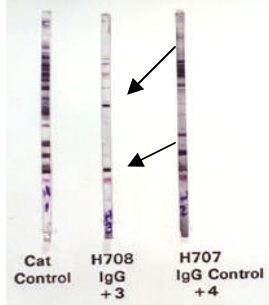
Veterinary Hospital Employees:

Case 3: Vet Tech: Chronic Uveitis

The son of a Long Island veterinarian, who worked in his father's practice, developed a chronic iritis and uveitis for 4 years which was preceded by a long-term lymphadenopathy. Despite numerous diagnostic tests, the etiology of the uveitis could not be determined. After reading the "Cats and *Bartonella*, Information for Cat Owners" brochure from this

laboratory he called us to discuss the possibility that *Bartonella* might be the etiologic agent for his uveitis. We agreed to test him, for experimental purpose only, for *Bartonella* antibodies by our western immunoblot test with the understanding that he would have our results confirmed by a licensed human *Bartonella* test. We found strong IgG antibody (see Figure below) to *Bartonella* that was confirmed by his physician (*B. henselae* 1:128). Azithromycin therapy resolved the chronic uveitis within 1 month.

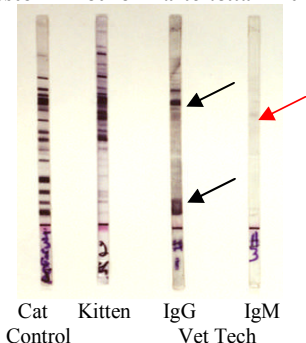
Western Blot for *Bartonella* Antibody



Case 4: Vet Tech: Cat Scratch Disease

A 28-year-old female veterinary technician working in Florida was scratched on the right arm by a 3-month-old kitten. Approximately 5 weeks later she developed a painful swelling in the right axillary lymph node. The technician called our laboratory to arrange to test the kitten for *Bartonella*. In addition, we agreed to test her, for experimental purpose only, for *Bartonella* antibodies by our western immunoblot FeBart® Test with the understanding that she would have our results confirmed by a licensed human *Bartonella* test. The kitten was strongly positive (+4) indicating infection. The technician was positive for IgG and IgM antibodies to *Bartonella* by our western blot test (see Figure below). Her antibody status was confirmed and her lymphadenopathy resolved within 1 month without therapy.

Western Blot for *Bartonella* Antibody



Cat Owners:

Case 5: Vet Tech: Conjunctivitis & Skin Nodule

A 33-year-old New Jersey veterinary technician received a scratch to her right hand. Several days later two raised non-erythematous nodules occurred and persisted for several weeks. Four weeks later she developed persistent chronic conjunctivitis (Figures 1 & 2). We found her positive by western blot however, a confirmatory antibody tested for *B. henselae* by her physician was negative. The reason for this discrepancy may be due to the fact that our western blot detects antibody to

all 5 feline *Bartonella* whereas the human test was specific for antibodies to *B. henselae*. The technician may have been infected with *B. clarridgeiae* and not *B. henselae*. No azithromycin was given and the signs persist.

Figure 1

Chronic conjunctivitis & scleral injection

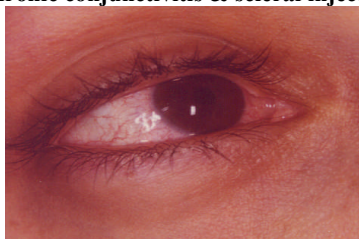
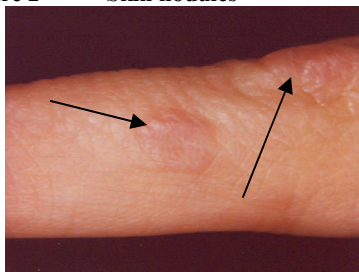


Figure 2 Skin nodules



Case 6: Cat Owner: Cat Scratch Disease

A 27-year-old married New Jersey women called us to test her cats for *Bartonella* after her physician diagnosed her with CSD and told her to “get rid of your cats.” She had 3 cats, all from shelter backgrounds, in the household. The owner’s history was alarming in that she was originally misdiagnosed with breast cancer due to a lump in her breast. She had been scratched on her right forearm by one of her cat’s hind claws. Four months later she developed fever, aches and fatigue along with pain in her right axilla. An abscess developed in the axilla along with a lump and tenderness in her right breast. Two weeks of Ampicillin did not improve her condition and she was diagnosed with breast cancer by ultrasound. Fortunately she sought a second opinion from an infectious disease specialist who quickly diagnosed cat scratch disease. Treatment with doxycycline for 2 months was successful. Two of the 3 cats were strongly positive for *Bartonella* on our test and the 3rd cat was a +2, questionable. All 3 cats were treated successfully with azithromycin. The woman tested positive by our western blot test and by a licensed human test while her husband tested negative. This case illustrates that invasive diagnostic test procedures, such as biopsies, may be needed in CSD cases to rule out more severe illnesses.

Case 7: Cat Owner: Bacillary Angiomatosis

A homeless HIV-infected drug addict presented to a NYC hospital with fever and red lumps on his face and chest after adopting a healthy 16-week-old stray kitten from the street. The kitten was heavily infested with fleas. We were asked to test the kitten for *Bartonella*. The kitten was strongly positive +4 by our test. In addition, the patient was also strongly positive for *Bartonella* on our test and was confirmed by a licensed human test. The patient was treated with erythromycin for 4 weeks and the fever and skin lesions resolved completely.

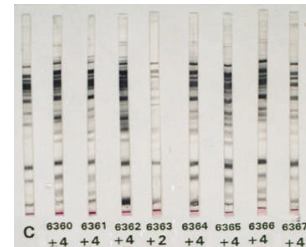
Case 8: Child: Cat Scratch Disease

A 6-year-old boy was admitted to a NYC hospital with fever and axillary lymph node enlargement. He reported having a 2-year-old cat but there was no history of a scratch or bite. The owners reported seeing no fleas on the cat but it had been adopted as a stray. Red papules developed on the boy’s arm followed by development of axillary lymphadenopathy. We tested the boy and found antibody to *Bartonella*, which was confirmed by a licensed human test. We then asked the parents if we could test the cat but were told “the grandmother’s Pit Bull ate the cat last week.”

Case 9: Child: Cat Scratch Disease

A 5-year-old boy, living in Michigan, was diagnosed clinically and by serology with CSD. We were called to test the 8 cats in the household. We found 7 of the 8 cats to be strongly positive (see Figure below).

Western Blot for *Bartonella* Antibody

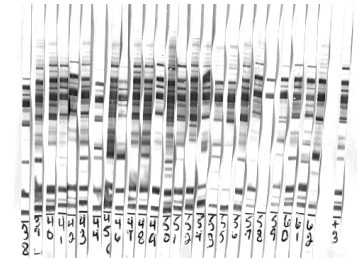


The authorities were threatening to remove the children from the household due to the numerous cats and the CSD occurrence. After we stated that the cats could be treated to remove the *Bartonella* infection the family was permitted to keep the cats and their children. All of the cats were treated with azithromycin.

Case 10: Cat Owner: Cat Scratch Disease

Twenty-four of 25 cats (Figure below), living in an Ohio household, where a person developed CSD and one cat had uveitis, were strongly positive for *Bartonella*. The danger to humans in such a household is significant.

Western Blot for *Bartonella* Antibody



References:

1. Arashima, K, et al: Rinsho Byori, 49: 906-10, 2001.
2. Kodick, D.L. et al.: J. Clin. Microbiol., 1813-8, 1977.
3. Sanders, A. & Ridder, G.J.: Cat-Scratch Disease-Not Only a Children’s Disease. 1st International Conference on *Bartonella* as Emerging Pathogens Tubingen, Germany, March 5-7, 1999.
4. Kaplan, S., et al.: Morbidity and Mortality Weekly Report: March 15, 2002, Vol. 51/No. 10.
5. Eskow, E. et al.: Archives of Neurology 58: 1357-1363, 2001.
6. Massei, F. et al. European Journal of Pediatrics 159: 416-419, 2000.

Bartonella references can be obtained at:

www.nlm.nih.gov/