NATIONAL VETERINARY LABORATORY

P.O. Box 239, 1Tice Road
Franklin Lakes, NJ 07417
877-NVL-LABS (877-685-5227)
www.natvetlab.com or .net

NEWSLETTER

Kids, Kittens, and *Bartonella*

Evelyn E. Zuckerman, Editor **Fall 2008** **Vol. 7, Number 4**

In This Issue:

In the Fall 2008 Newsletter, we will discuss the unique relationship between kittens and kids. Both kittens and kids are energetic, adventurous and, at times, reckless (Figure 1). This combination can lead to injury to the young of either species. We will review the dangers of kittens transmitting their *Bartonella* infections to children and the possible disease ramifications of this zoonotic cross-species transmission. A recent JAVMA article recommends that veterinarians take a proactive role in educating clients on prevention of zoonotic diseases.[1] We recommend that all kittens be tested for *Bartonella* at their first examination.

Figure 1. Yes, there is a unique relationship between kittens and kids!

Bartonella Diseases of Children:

As with the feline leukemia virus in veterinary medicine, there is often a misuse of the terminology describing *Bartonella* diseases in humans. Many veterinarians say they are doing a "feline leukemia" test when in fact they are testing for the presence of the feline leukemia virus, which causes many more diseases than leukemia in cats. Similarly, physicians often describe all *Bartonella* infected people as having "cat scratch disease" when many never show the classical signs of cat scratch disease (CSD), but instead have severe sequelae of *Bartonella* inflammatory diseases of various organs, i.e. chorioretinitis, encephalitis, cholangiohepatitis, etc. These individuals should be described as having "bartonellosis", an inflammatory disease caused by *Bartonella*.

The older literature often describes CSD as a "self limiting" disease of children.[2] This is due to the well know classical signs consisting of fever, papule at the scratch or bite site and, lymphadenopathy. Taken together, these signs constitute the CSD prodrome- the earliest consistent signs of a disease. Most pediatricians are well aware of these signs which indicate contact with cats and suggests CSD. They are less familiar with the more serious sequelae of *Bartonella* infection in the absence of earlier prodromal signs of classical CSD.[12] Thus, bartonellosis may be undiagnosed allowing severe health consequences of seizures, eye problems, heart disease, and rarely, death to occur in children.[3-9]

Figure 2

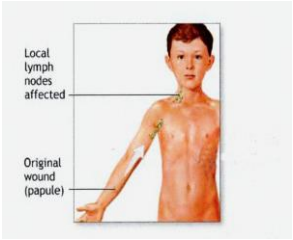

CSD prodrome:
Fever, skin papule and lymphadenopathy

CSD Clinical Signs: In our study of 84 cases of *Bartonella* infection in people, most (80%) of the 21 infected children developed classical CSD with one, or a combination, of the prodrome signs of CSD: fever, skin papule at the scratch or bite site, and regional lymphadenopathy (Figure 2).[4] However, 20% of the infected children did not show signs of classical CSD and developed only severe sequelae in various organs (Figure 3).

Figure 3

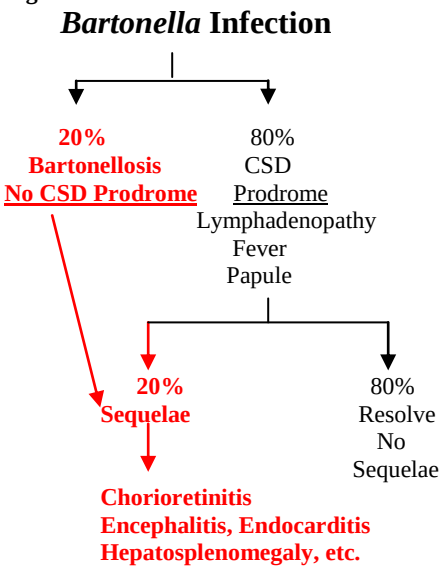

Bartonella Diseases of Children:

Cat Scratch Disease:[2-6]
- Fever
- Papule at scratch or bite site
- Lymphadenopathy- regional

Neurological Diseases:[2-9]
- Encephalitis
- Meningoencephalitis
- AIDS encephalopathy
- Aggression
- Cognitive dysfunction
- Status epilepticus
- Coma

Ocular Disease:[2, 4, 12]
- Chorioretinitis
- Optic nerve neuritis
- Uveitis
- Disciform keratitis
- Conjunctivitis
- Parinaud's oculoglandular syndrome
- Orbital abscess

Heart Diseases:[10, 12]
- Endocarditis
- Valvulitis- vegetative
- Myocarditis
- Pericarditis

Major Organs Involvement:[2-4, 9, 12]
- **Liver:**
  - Bacillary peliosis hepatis
  - Granulomatous hepatosplenic syndrome
- **Spleen:**
  - Splenic bacillary angiomatosis
- **Kidney:**
  - Necrotizing glomerulonephritis
- **Intestines:**
  - Inflammatory bowel disease
  - Bacillary angiomatosis

Respiratory Diseases:[2, 9, 12]
- Pulmonary granuloma
- Pulmonary infiltrates

Musculoskeletal Diseases:[1, 4, 12]
- **Muscle:**
  - Bacillary angiomatosis
  - Myositis
- **Bone:**
  - Osteomyelitis
- **Joints:**
  - Arthritis/ Polyarthritis

Skin Disease:[1, 4, 12]
- Bacillary angiomatosis
- Cutaneous rash- Henoch-Schenlein purpura
- Cutaneous granuloma annulare

Other:[11, 12]
- Fever of unknown origin
- Co-infection with Lyme disease
- Mononucleosis-like syndrome

Why are kittens more likely to transmit *Bartonella* to kids?

More than 50% of kittens originate as strays or from shelters or rescue groups where the exposure to fleas carrying *Bartonella* is common. Thus, CSD (bartonellosis) cases peak between August and October. *Bartonella* are found in the blood plasma, inside erythrocytes and endothelial cells and in tissues of infected kittens. In order to be transmitted to people, the organism must be present on the claws (scratch), in the mouth (bites) or on the fur (contact- no abrasion) of infected kittens. Infected kittens are rapidly growing and have changing dentition leading to the probability that *Bartonella* can leak into the oral cavity. The loss of kitten teeth or oral trauma due to rough play, chewing and playful fighting, can lead to *Bartonella* in the oral cavity. Cats groom themselves frequently and thereby probably deposit *Bartonella* organisms from the oral cavity onto their fur or claws. The fact that kittens and children are both more playful toward each other presents the conditions needed for the zoonotic transmission from kittens to children. Boys tend to play more roughly with kittens than do girls which is reflected in the higher incidence of CSD and bartonellosis in boys.

Bartonella Cases in Kids:

Cat Scratch Disease Occurring Simultaneously in a 6-Year-Old Girl and Her Father.

We investigated the simultaneous development of CSD, without sequelae, in a 6 year old girl and her father. The family, living in the southeast, adopted a healthy 3-month-old stray kitten with fleas from a neighbor. The father was scratched on the face by the kitten but there was no known scratch or bite of the daughter. One month later the father and daughter developed severe flu-like symptoms of fever, lymphadenopathy, extreme weakness, and severe muscle and joint pain (CSD prodrome). The daughter developed an enlarged painful axillary lymph node while her father developed an enlarged lymph node under his chin. The daughter's fever fluctuated between 102-105°F for 1 month despite antibiotic therapy. She was hospitalized twice for a total of 4 days. During this time the father had a persistent fever of 102°F. When the family's pediatrician discovered that the family had recently adopted a kitten he ordered a *Bartonella* antibody test for the girl. The result was a strong positive IgG titer of 1:2,048. The pediatrician diagnosed CSD in the girl and her father. The father's *Bartonella* IgG antibody test was positive at a titer of 1:1,024. The daughter's lymph node was drained of pus and she and her father were treated with Azithromycin for 21 days. Both rapidly recovered and no serious sequelae developed in either the daughter or her father. The girl missed 3 weeks of school and the cost of her illness was $16,000 while the father's illness cost $500. Our *Bartonella* test of the kitten was positive.

Fatal Meningitis and Encephalitis due to *Bartonella henselae* bacteria.[8]

A four-year-old healthy girl, living in Tennessee, began to have severe seizures. She had not been scratched or bitten by a cat but had recently visited her grandmother, who had several cats and kittens. Two weeks before the onset of her illness she developed a fever, cervical lymphadenopathy (CSD prodrome) and had cognitive problems the day before the seizures began. She was treated with antibiotics by the family physician without a diagnosis. Later, at a medical center, she was treated aggressively for the seizures and the fever of unknown origin. Her condition rapidly deteriorated and she died without a specific diagnosis. At autopsy there was marked cerebral edema, pleural effusion, ascites, and white-tan lesions on the surfaces of the liver and spleen. Histopathological examination revealed multiple granulomatous lesions in the brain, lungs, liver, spleen and meningitis and encephalitis. Cultures were sterile but Warthin-Starry stains of the brain and liver revealed rod-shaped bacilli consistent with *Bartonella spp*. PCR and Southern blot of brain tissue was positive for *Bartonella henselae*. This rare case shows the severity and rapid development of the sequelae of *Bartonella* infection in a healthy immunocompetent child.

Human Bartonellosis: Diseases Caused by Feline *Bartonella*- 84 Cases.[4]

The following is a summary of the *Bartonella* diseases that we studied in children and presented at the 5th International Conference on *Bartonella*.

Aim: The aim of our study was to determine how cats transmit *Bartonella* to people and the signs of *Bartonella* illnesses in children and adults. We also wanted to determine if veterinarians discussed the zoonotic dangers of feline *Bartonella* with their clients **BEFORE** they became ill, and to determine if their physicians were knowledgeable about *Bartonella* diseases.

Results:

All 84 cases confirmed by serology or biopsy.
21/84 cases (25%) were pediatric cases: <19 yrs.
2 cases occurred in veterinarian's children.

Cats that transmitted *Bartonella* to children:

95% *Bartonella* Fe*Bart* WB antibody +.
95% originated as stray/shelter cats.
43% were **kittens** less than 1 year old.
81% were **healthy** kittens or adult cats.

Mode of Transmission:	**Child**	**Adult**
Cat- no known scratch/bite:	71%	49%
Cat scratch:	19%	39%
Cat bite/licking:	10%	6%
Ticks:	0%	6%
Human *Bartonella* Disease:		
CSD- no sequelae:	67%	56%
CSD- with sequelae:	19%	25%
Bartonellosis- only sequelae:	14%	19%
Treatment & Outcome:		
Hospitalized:	43%	35%
No treatment or under treated:	38%	25%
Serious sequelae:	19%	25%
Vision loss- % permanent:	0%	10%

Physician Awareness:

Physicians needed for the diagnosis: Average 2.5

One: (Pediatrician)	48%
Two:	19%
Three or more (up to 8):	33%
Veterinarian- diagnosed (fathers):	2
Family member- Diagnosed:	3

Veterinarian Awareness:

Did your veterinarian ever discuss the public health aspects of *Bartonella* infection and kittens (cats) with you BEFORE your child was infected with *Bartonella*?

No 16/21= 76%
Yes 5/21= 24%

Conclusion: In general, children in our study developed slightly milder clinical syndromes, with less severe sequelae, than adults. However, they were more often hospitalized for their illnesses and received no treatment or were treated for shorter periods than the adults. Veterinarians and physicians need to become more aware of the dangers and diseases of feline-derived *Bartonella* infection in children.

The CDC and the AAFP do not recommend testing healthy cats for *Bartonella*. We feel this has led to needless *Bartonella* infections and severe disease consequences in children and adults. Although rare, 2 reported fatalities in children have occurred from *Bartonella* infections.[8, 9] We urge veterinarians to discuss the public health ramifications of kittens, kids and *Bartonella* with their clients and recommend *Bartonella* tests of all cats.

References:

1. Lipton, BA, et al. A survey of veterinarian involvement in zoonotic disease prevention practices. JAVMA. 233, 1242-1249, 2008.
2. Daniels, WB, and Macmurray, FG. Cat scratch disease; report of one hundred sixty cases. J Am Med Assoc. 154: 1247-51, 1954.
3. Massei, F. et al. Widening of the clinical spectrum of *Bartonella henselae* infection as recognized through Serodiagnostics. European Journal of Pediatrics 159: 416-419, 2000.
4. Hardy, WD, Jr., and Zuckerman, EE. Human bartonellosis: diseases caused by feline *Bartonella*- 84 cases. 5th Intern. Conf. on *Bartonella* as Emerg. Pathogens. Pacific Grove, CA, September 2-7 2006.
5. Reynolds, MG. *et al*. Epidemiology of cat-scratch disease hospitalizations among children in the United States. Pediatr Infect Dis J.24:700-704, 2005.
6. Noah, DL, *et al*. Cluster of five children with acute encephalopathy associated with cat-scratch disease in south Florida. Pediatr Infect Dis J. 14: 866-9, 1995.
7. Armengol CE and Hendley, JO. Cat-scratch disease encephalopathy: a cause of status epilepticus in school-aged children. J Pediatr 134: 635, 1999.
8. Gerber, JE, Johnson, JE, Scott, MA, and Madhusudhan, KT. Fatal meningitis and encephalitis due to *Bartonella henselae* bacteria. J Forensic Sci 47: 640-4, 2002.
9. Fouch, B, and Coventry, S. A case of fatal disseminated *Bartonella henselae* infection (cat-scratch disease) with encephalitis. Arch Pathol Lab Med. 131: 1591-94, 2007.
10. Gouriet, F, *et al*. From cat scratch disease to endocarditis, the possible natural history of *Bartonella henselae* infection. BMC Inf Dis. 7:30-35, 2007.
11. Massei, F. et al Pseudoinfectious mononucleosis: a presentation of *Bartonella henselae* infection. Arch Dis Child. 83: 443-4, 2000.
12. Tsuneoka, H., and Tsukahara, M. Analysis of data in 30 patients with cat scratch disease without lymphadenopathy. J Infect Chemother 12:224-226, 2006.

More references are available at:
www.nlm.gov or www.scholar.google.com

Writing newsletters is exhausting!